



GREATER GLASGOW HEALTH BOARD
WESTERN INFIRMARY / GARTNAVEL GENERAL HOSPITAL UNIT

CLINICAL TEACHING CASE STUDY

**CHILDREN'S
HOMEOPATHY
CLINIC**

CONFIDENTIAL

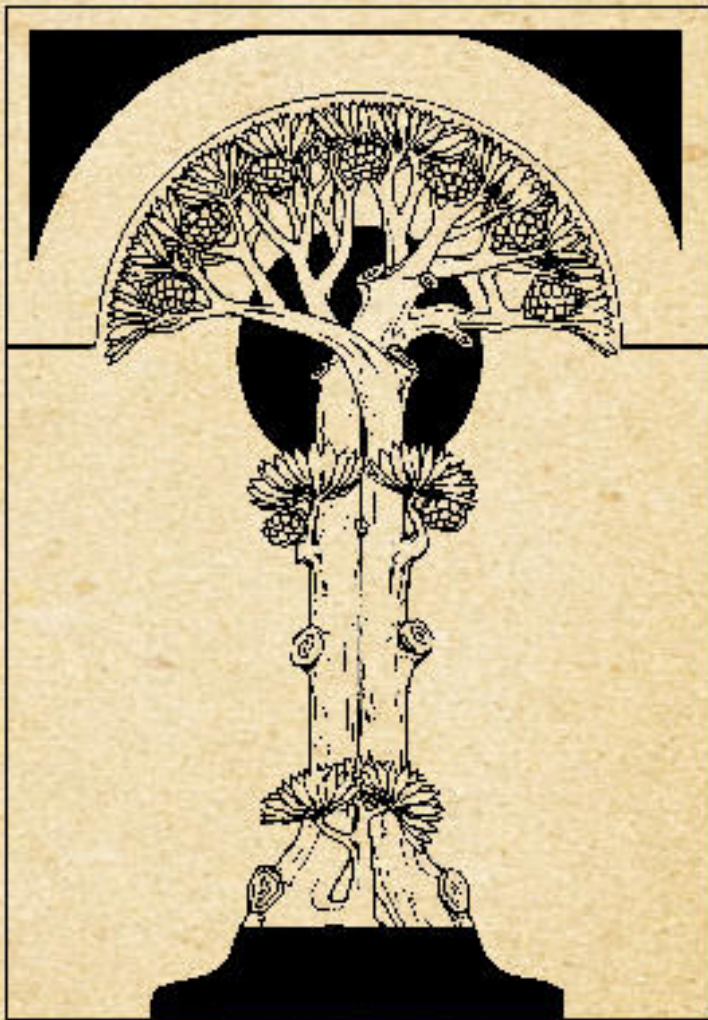
Name: Shane M.

Illustrative Case No. 9

CLINICAL TEACHING CASE No 9.

Respect Patient Confidentiality

Discussion or disclosure is not permitted, except within your training group.

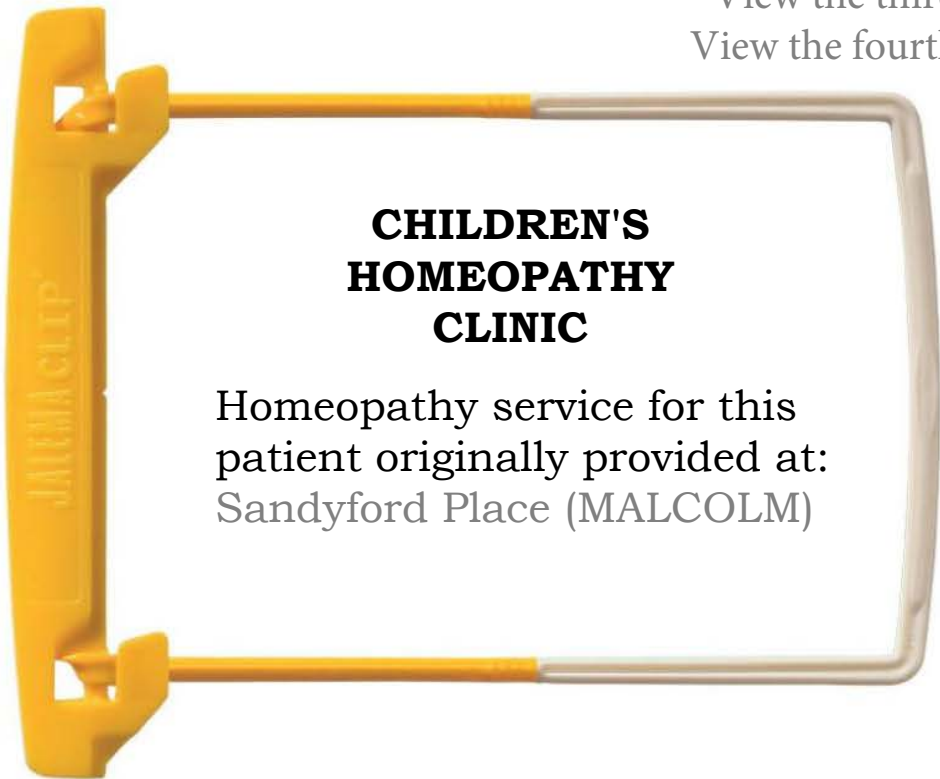

Centre for Integrative Medical Training 2021
Provided on licence to registered students of
Homeopathy Property of CIMT. All rights reserved.

Name: **Shane M.** Presenting Complaint / Principal diagnosis:
Age at First Consultation: 6 months Eczema

INSTRUCTIONS FOR LEARNERS

Study the referral and [view the first consultation](#) for this case in week: **6**
[View the first review](#) consultation and consider further treatment in week: **7**
[View the second review](#) consultation in week: **8**
View the third review consultation in week:
View the fourth review consultation in week:



After you have added your own notes to this interactive pdf file, be sure to save it to your computer. Once the case review for this patient has been concluded, save the final copy to your training portfolio.

INDEX

- Referral / Correspondence GP LETTER
- Case Recording Sheets
- Original Written Notes (First Consultation)
- Investigation Reports(empty)
- Repertoristions & Searches (empty)
- Clinical Audit / Outcome Reports (empty)
- Clinical Photographs / Images
- Miscellaneous (empty)

Shap Medical Practice

Shap Medical Practice,
Peggy Nut Croft,
Shap,
Penrith,
CA10 3LW
01931 716230

Glasgow Homeopathic Hospital
1000 Great Western Road
Glasgow G12 0XF

10 March ...

Dear Doctor,

Re Shane M Crosslands, Penrith, CA10 2RQ, Date of Birth 17/10/...

This little boy was born by Ventouse after normal pregnancy and fared well neonatally. Around the time of his first DPT vaccination he developed eczema and mild cradle cap. His skin may have aggravated post-vaccination and we tried Thuja 30c with no obvious benefit.

Although his head was the main area affected to begin with, Shane's eczema became more diffuse in spite of regular emollients and hydrocortisone cream.

He was reviewed acutely in January with what appeared to be infected eczema, mainly on his head and was reviewed by the dermatology unit in Carlisle. Their initial management with combined topical steroids and anti-bacterials did not prove to be particularly helpful and Shane was changed to Fucidin HC and fared better with that.

His skin is currently managed with Hydrocortisone 1%, Diprobase and Ichthopast bandages to his limbs.

His mum is concerned about the long-term use of topical steroids and since his skin is obviously still fairly active, I wonder if you would see Shane and advise further on possible homoeopathic treatment.

Yours sincerely

Dr.

FIRST CONSULTATION

Name: Age:

You can annotate this recording sheet while you view the video case. You may find it more convenient, however, to download and print the recording sheet from supplemental materials and patch in the history by hand.
Complaint:

History of Present Illness:



https://youtu.be/ZM_467hI79Y

Use the link above to access the Consultation Video. Size the video player window on your computer desktop so that you can simultaneously make entries into this case recording sheet.

Personal:

Menstrual History:

Family History:

Examination:

FIRST CONSULTATION

HOMEOPATHIC SYMPTOMS

GENERALS

Heat: Cold: Perspiration:
Time: Weather:

STOMACH

Appetite: Disordered:
Aversions: Thirst:
Desires:

SLEEP

PARTICULARS

Head Stomach
Eye Abdomen
Ear Bowel
Nose Genito-urinary
Throat Back
Respiratory Extremities
Skin

MIND

INDEX

CORRESPONDENCE

NOTES

REPORTS

OTHER

FIRST CONSULTATION

Continuation sheet

Patient name / id

FIRST CONSULTATION

Continuation sheet

Patient name / id.

INDEX

CORRESPONDENCE

NOTES

REPORTS

OTHER

FIRST REVIEW

Continuation sheet

Patient Name / id.:

Time since first seen:



<https://youtu.be/49gGz3djP3o>

SECOND REVIEW

Continuation sheet

Patient Name / id.:

Time Since Last Review



<https://youtu.be/d76c34rYbVE>