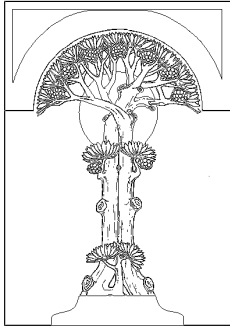


Centre for Integrative Medical Training
In Association with London Integrated Medical Health Education



Intermediate Course in Medical Homeopathy

A Blended Course in Homeopathic Medicine for Healthcare Professionals

Unit 36

Materia Medica Studies and Therapeutic Pointers for Week 4

Unit 36

As part of this Semester's exploration of the mineral salts, this little unit provides an opportunity to focus on the Calcs. You may wish to review Gabriela Rieberers presentation which formed an optional section in your Foundation Studies. https://youtu.be/_VOOOv2Dy-M

If you have time, have a look at the following case examples and write in you chosen remedy for each case. Exemplar answers are provided at the end of this module. To get the most out of this exercise, don't refer to the 'answers' until you have worked all the cases provided.

SAQ. 36.1

In the pages that follow you will find a series of children's cases in outline. Each child had been successfully treated with one of the Calc salts.

In the live clinical setting there is always an element of exploration and most of these children did not receive their similimum at the first interview.

Case	Your suggested remedy	Actual prescription & notes
1. Christina C.		
2. Lindsay B.		
3. Benjamin M.		
4. Michael W.		
5. Matthew D.		
6. Alan M.		
7. James C.		
8. Emma W.		

1. Clinical Case Study: Christina C. Aged 4

Eczema since infancy.

PMH: LUSCS: one of two non-identical twins

FH: Aunt had eczema

Older sib had eczema in infancy which resolved

Maternal grandparents alive, Paternal grandparents both died of carcinoma

Other problems:

Constipation: cries during stool

Itch < night: GP prescribed antihistamines

Rubs her hands on the carpet.

Fairly active eczema in antecubital fossa

Warm-sensitive and 'warm - blooded'. Likes to uncover much of the time. Throws bedclothes off.

Likes eggs

Teeth are strong and well shaped

Enjoys Company, but can be quite dominant at times

Mood generally good, but takes a while to come out of a tantrum.

A bit stubborn.

Goes to playgroup and gets on fine there

Saw a homeopath who issued Phosphorus, and Tub bov. in stat doses.

Treatment:

Slight improvement with Sulphur, not maintained.

Tried Sulphur in low potency repeated: slight improvement but constipation did not improve and became more irritable in mood.

Better response to Sanicula aqua 12/3 but no further improvement on repetition.

Excellent response to Calc phos.

[letter]

CHRISTINA C. 14.12.08.
DR MALCOLM,
I RECEIVED YOUR LETTER REGARDING CHRISTINA AND I AM WRITING TO LET YOU KNOW THAT HER SKIN HAS BEEN CLEAR OVER THE LAST FEW MONTHS. SHE DOES NOT APPEAR TO BE SCRATCHING HER HANDS AND ARMS AS MUCH. HER SKIN ON THE SURFACE STILL LOOKS DRY BUT IT DOES NOT APPEAR TO BE UPSETTING HER AS MUCH.

2. Miss Lindsay B. (B167) Aged 14

First appointment: 07/08/2001

Asthma. Worse since recent chest infection treated with penicillin.

Has been on oral steroids and inhaled steroids have been increased.

Was acutely unwell for a month with chest heaviness and a cough productive of thick green sputum.

Breathing was very laboured with constant wheeze and voice reduced to a croak.

Remains constantly tired. Cervical glands swell up - especially when fatigued.

PMH: Problems with chest since early childhood. Treated mainly with inhalers.

Only good phase was in last years of primary school.

(Mother and father divorced when she was in Primary 5. She moved to Glasgow for first year of secondary education)

Infections have been getting worse.

Persistent sore throat and L ear frequently feels blocked

Nose chronically snuffly and often blocked.

Allergies:

Dust << respiratory symptoms

Feather pillows << respiratory symptoms

Cats - urticaria

Slight eczematous eruptions appear concomitant with aggravations of her chest.

- Only comes back with stress or infection.

Recent stress: death of grandmother in October.

Head: No headaches

Eye: itching - eyes go red (< house move ? Dust)

ENT catarrh between asthma attacks

throat always sore - white lumps on pharynx

RS: cough and wheeze < dry, cold weather and excessively hot weather

Currently slight expectoration: still greenish/yellowish

GU Back pain during periods (since menarche last year)

Generals: constantly cold.

Light build. Blond. Pale.

Cold hands and feet - even in warm weather.

Gets pale white, or mottled bluish hands.

Tires in the afternoon: 2 - 4pm < Could go to sleep. Energy picks up a bit later on.

Appetite: variable

D: crisps, pasta and chocolate. Drinks a lot of water. No tea or coffee.

A: not fond of highly seasoned food. No obvious food intolerances.

Slight improvement at the seashore.

Mind:

Unrelaxed in interview

Can get very angry. Can be hurtful to others.

Sharp verbal outbursts if someone pushes her to the limit.

Can hang on to anger. Tendency to retrospection.

Priorities: seeking security and stability. Wants financial security and a nice home in the future.

Treatment:

Review: 11/09/2001

Was very tired after taking the first remedy. This slowly settled.

Chest > Mucus .

Mood a lot better overall

Also didn't get back pain with period

Tiredness ++ again after second remedy for 1-2 days. Picking up.

Sleeping OK

Appetite OK (had been eating too much)

Treatment:

Review: 9 Nov. 2001

A lot better. Chest has been fine. No recent chest infections.

Emotionally more balanced.

MP has been erratic. No back pain.

Not weepy or irritable.

Treatment:

1. RESPIRATION - ASTHMATIC
2. EXTERNAL THROAT - SWELLING - Cervical Glands
3. ABDOMEN - SWELLING - Sides
4. EXTREMITIES - SWELLING - Lower limbs - menses, during
5. GENERALS - MENSES - before
6. HEAD - ERUPTIONS
7. EXTREMITIES - COLDNESS - Hands
8. GENERALS - AFTERNOON - 14 h
9. MIND - COMPANY - desire for
10. GENERALS - COMPLEXION - fair, blond, light - lax fibre, with
11. EXPECTORATION - YELLOW
12. MIND - ANGER - sudden

	1 lob-s.	2 arum-m.	3 calc-sil.	4 grin.	5 merc-i-r.	6 sul-i.	7 cupr.	8 wye.	9 asc-c.	10 sul-ac.	11 bov.	12 iod.	13 dig.	14 spig.	15 zinc-val.	16 apoc.	17 graph.	18 zinc-p.	19 calc-ar.
	1050	939	935	819	792	778	718	704	675	667	664	661	658	651	645	620	618	618	603
1.	1	1	1	1	1	1	3	1	1	2	2	2	2	1	1	-	2	1	1
2.	-	-	1	-	-	1	1	-	-	1	1	2	-	2	-	-	3	-	-
3.	-	-	-	-	-	-	-	-	-	-	-	-	-	-	-	-	-	-	-
4.	-	-	-	-	-	-	-	-	-	-	-	-	-	-	-	1	1	-	-
5.	-	-	1	-	-	-	3	-	-	1	3	1	1	1	-	-	1	1	-
6.	-	-	1	-	-	1	1	-	-	3	2	-	-	-	-	-	3	1	-
7.	1	-	1	-	1	1	2	-	-	1	2	3	2	1	-	1	3	1	3
8.	-	-	-	-	-	-	-	-	-	-	-	-	-	-	-	-	-	-	-
9.	-	-	-	-	-	-	-	-	-	-	1	-	-	-	-	-	-	1	1
10.	-	-	-	-	-	-	-	-	-	-	-	-	1	-	-	-	3	-	-
11.	-	1	1	1	2	1	1	-	-	1	1	1	1	1	-	-	1	1	-
12.	-	-	-	-	-	-	-	-	-	-	-	-	-	-	-	-	-	-	-

3. Case Study: Benjamin M. Aged 6.

Skin eruptions since the age of 6 months.
Mother tried exclusion diets without much success.
Wheals, red patches. Rough areas.

PMH: SVD at term. No neonatal problems

FH: Father has eczema, and history of asthma in fathers family.

No seasonal difference
Warm blooded, sweats fairly freely at night
No glandular swelling
Catarrhal. Bad breath in the morning.
Snores, mouth breather

Likes: pizza, spaghetti, mushrooms, sauces

Outgoing, sensitive, friendly, creative, 'talented' (according to mother
Wants to be a pop singer. Excited about his part in the Carol Concert.
Seeks approval and attention
Interrupts mother.
Pale, fine teeth. Fine hair.
Looks a bit tired and baggy eyed.

Treatment:

Skin generally better. Overall vastly improved. Remains a bit catarrhal.

4. Case Study - Michael W.

Eczema since infancy

Developed an allergy 10 months ago.

- gets blotchy in the afternoon which is resolving by night.

Skin on the face particularly dry for past 3 months.

Dry skin, active eruptions outer aspect of legs.

PMH Asthma and hay fever

UTI recurrently at age of 1 ½ attended Yorkhill hospital for investigation

FH No sibs. Mother has hay fever, Uncle asthmatic. Maternal GF had psoriasis

Clinically allergic to lanolin, animal fur and wool

Grasses irritate.

Skin unstable in the summer

Sun seems to aggravate, causing a blotchy heat rash.

Winter: skin becomes dry with hacks on the hands and feet.

Desire for sweets which may aggravate

Aversion to eggs and fruit

Flatulent in the morning on getting up. Tummy swells a lot.

Not especially catarrhal and not snoring at night.

Good teeth with an even bite.

On inhalers: Wheezy during viruses, and with sudden changes of air temperature

Mind: Talkative, Friendly, Play boisterous. Sense of humour.

Treatment:

Review: Has been doing very well. Skin globally less dry and active. Happy.

5. Case Matthew D. Aged 13.

Has had a difficult winter. Recurrent colds and viruses. Under par. Sullen. Not much eye contact. Problems with his ankles and feet.

Currently off school - Recent tooth extractions. 'Small jaw and teeth crowded' Due to have a brace fitted. Mouth feels clogged up with a bad taste (bitter) at the base of the tongue.

Tired when he comes home from school. Catarrhal. Recurrent sore throat and ears. C/o sore throat on waking. Nose can get blocked up recurrently. Occasional nosebleeds - used to get them a lot, only occasional now. Chicken pox 1 year ago - slow to recover.

Has been feeling weak. No fevers, not much sweat. Feels the school stuffy and overcrowded.

Appetite variable: likes milk, appetite only picks up as the day goes on - often doesn't eat until 4pm. Averse salt.

Bones click. growing pains in ankle and some osteophytic growth on the calcaneous.

Logical. Quiet. Would like to study chemistry or computing. Likes robotics and programming. Likes to be seen to be conforming. Wants to be accepted. Likes finished work. Fearful of clowns since infancy - finds them sinister - not true and honest.

Treatment:

Review:

Feeling better overall. Energy fine now. Not tired. Fewer colds. Doing more sports - ankles still 'feel weak' Still inclined to eat more at night.

6. Case Study: Alan M. Aged 14.

Eczema
Fatigue
Difficulty concentrating at school

PMH:
ASD at birth
Lazy left eye
Adenoidectomy
Twisted ankle and incurred a haemarthrosis 2 years ago.
Wheezy and sneezing on contact with feathers.

Drugs:
Becotide inhaler ii puffs qds
Dalcin T topically

FH
Father died of cancer 2 years ago
Family history of heart disease

Some sweats at night. Generally tolerant of warmth
Likes: sweet, lasagne. Has gone off salt.

Mind:
Easily provoked to anger
Anxious at outset of interview
Strong feelings about racism and sectarianism
Slowish speech
Reserved
Quite caring

Treatment and review: some response to Natrum mur.
Attention still wanders
Mood less changeable
Likes: milk, cereal, chocolate, eggs
Chillier than before
A bit catarrhal
Hands tend to be clammy

review: see letter

Improved further with repetition of the remedy.

Dr Russell S. Malcolm
MB ChB, BA MFHom.
29 Grange Road
Edinburgh
EH9 1UQ

Dear Dr Malcolm

I am sorry for the delay in my reply to your initial letter.

Since the last appointment, there has been many changes which I think were caused by the last batch of sachets that you gave me.

The changes that I have come across are as follows. My skin has cleared up. This started happening about 2 to 3 weeks after I took the sachets. Eating habits are more consistent. I am eating about the same time each day and also feel hungry just before these times. I generally feel a lot healthier, cleaner and energetic. I am sleeping without waking up during the night. Reading and talking a lot more, with greater ease. I am drinking more fluids, but less fizzy drinks.

These changes are what I have personally found happening. But my parents may have other comments! Would it be possible for me to have another appointment with you in the near future, hopefully before I go on holiday from the 7 July.

Yours sincerely

Allan

7. Clinical Case: James C. Aged 5

Dry skin became a problem at 6 months

Started on the face.

Has become gradually worse - now involving wrists, legs and neck.

Wool aggravates

Asthmatic - currently stable

Viral URTI aggravate

Currently treated with:

Fucibet

Hydramol

Becotide inhaler bd

Ventolin inhaler prn

Warm blooded. Heat aggravates. Perspires on exertion.

Thirsty for water ++, milk +, juice +

Colourants in sweets aggravate his skin

Averse eggs

Likes: meat, spaghetti, fruit, carrots

Not catarrhal

Teeth good

No significant glandular swelling

Large square head

Robust frame

Excitable

Stubborn and a bit moody.

Sits engaged in play

Watches before joining in.

Boisterous. Likes football.

Treatment:

Review:

After remedy scratched for 2 days. skin looked a bit raised then settled. URTI shortly afterwards.

Fine in himself. No hydrocortisone now, just moisturisers. Skin has cleared from above downwards.

Skin on his legs presently clearing. Mood OK. Sleeping a lot better.

8. Clinical Case: Emma W. Aged 5

Discharging right ear. had complained of pain in right ear until discharge started. Initially clear discharge then creamy, then a little blood.

Pallor. Cough. Sore throat.

Quite a few cervical lymph nodes.

PMH

Chickenpox

No known allergies

No current medication

Very occasional slight nosebleeds

Tires easily. Flaked out after school.

Sleeping well.

Kind, loving child - but seems very shy here.

Delicate, tall for age. Slender.

Dislikes scarves and hats.

Gets on well with other children, prefer gentle quiet friends.

Imagination games.

Treatment:

Review: discharge cleared quickly. No further infection. Energy up. Accompanied family on holiday - no problem with flight.

SAQ 36.1 suggested answers

It is difficult to represent the essence of a child constitution on paper. Nevertheless, I hope you were able to identify the contrasting features in some of these cases and identify the likely constitution.

Here are my prescriptions. Don't take them too seriously, since it is possible that some of these children would have responded as well - perhaps even better - to another salt, who knows.

Case	Your suggested remedy	Actual prescription & notes
1. Christina C.		<i>Calcarea phosphorica</i>
2. Lindsay B.		<i>Calcarea silicata</i>
3. Benjamin M.		<i>Calcarea phosphorica</i>
4. Michael W.		<i>Calcarea sulphurica</i>
5. Matthew D.		<i>Calcarea silicata / fluorica</i>
6. Alan M.		<i>Calcarea carbonica</i>
7. James C.		<i>Calcarea sulphurica</i>
8. Emma W.		<i>Calcarea silicata</i>